

Notes on the Windpipe

Hermes C. Grillo, MD

Thoracic Surgery, Massachusetts General Hospital, Boston, Massachusetts

As relief on the facade of the Cathedral at Orvieto depicts the birth of Eve (Fig 1). God, very much the thoracic surgeon, works through a respectable thoracotomy. Dr Edward D. Churchill first brought this interpretation to my attention, although his photograph of it was uncluttered by plastic shields now made necessary by the new barbarians. Although this may well have been the first thoracic surgical procedure, we generally recognize our specialty as a relatively new one. After the employment of Sauerbruch's negative pressure chamber and various positive pressure devices such as those of Brauer and Robinson [1, 2], endotracheal intubation finally allowed the thoracic surgeon to get in and out of the chest with a surviving patient. Dr Churchill once laughingly called his pioneering generation "buccaneer surgeons." They were able to slash their way into the chest, thanks to the endotracheal tube, and in it they found the treasures of pulmonary, esophageal, and mediastinal pathology. These prizes of a previously inaccessible area of surgery lay before them to be grasped. About 25 years later another gadget—the heart-lung machine—permitted a second wave of buccaneers to plunge into the heart. Once again much good was done and great reputations were made.

Although tracheostomy is one of the most ancient of operations, the windpipe was all but ignored during this early surge into the chest. Ambroise Paré sutured two severed cervical tracheas in the 16th century [3], unfortunately without survival, but in the first burst of modern thoracic surgery, little was done with the trachea. There were some reports of resections with end-to-end anastomosis, usually for short lesions, and numerous lateral excisions with patching of the tracheal defect. Early recurrence of tumor was the rule. In the laboratory and less often in the operating room, attempts were made to replace the trachea with a variety of prosthetic materials, alone or combined with native tissues [4].

Why was this the case? Why so little progress? First, there were anatomical difficulties in reconstruction. It was believed to be impossible to resuture predictably the trachea if more than 2 cm were resected [5]. It was also believed that cartilage healed poorly. Second, it seemed difficult to maintain anesthesia and oxygenation during extensive surgical procedures on the trachea. And last, but perhaps most important, few tracheal lesions were seen. Primary tumors of the trachea were rare then as now, and operation was not considered for secondary

neoplasms. Benign strictures were also rare. The challenge was therefore limited.

In the last 25 years, the following changes have occurred in tracheal surgery.

1. All but the most extensive lesions are now surgically removable.
2. The techniques of tracheal surgery and anesthesia have been developed and standardized to a considerable degree.
3. The pathology of tracheal diseases, both neoplastic and inflammatory, is much better understood and therefore more amenable to appropriate treatment.

These changes resulted from the efforts of numerous surgeons in a number of countries. I shall relate to you a rather personal account of this last buccaneering sally of thoracic surgery—the attack on the trachea over the last 25 years. I describe this as a personal account because I have no intention of slighting the many contributors whom I shall not mention in this brief and anecdotal account. It is not a review of the development of tracheal surgery. I also wish to present this account as an extended exercise in experimental surgery. In it are intertwined the threads of laboratory investigation and clinical research, with the story moving back and forth from laboratory to operating room as problems arise. There are some lessons to be learned from this experience. I hope the story will be of interest, especially to young surgeons embarking on careers in thoracic surgery. For the rest of you who might now be groaning silently, "There he goes, talking about the windpipe again," I can only point out that I am simply recognizing that this subject is why I'm standing before you here today.

The Ether Dome of the Massachusetts General Hospital is the hospital's original operating room atop the Bulfinch Building (Fig 2). Here is where general anesthesia for surgery was first publicly demonstrated to the medical community and from where it spread throughout the western world. I was seated in a back row of the Ether Dome, now a teaching amphitheater, one Tuesday morning in 1961 at the medical-surgical pulmonary conference when a patient with a cylindroma in the lower trachea was presented. The lesion was extensive, and lateral resection with appropriate patching was proposed. Dr Churchill commented on the problems of leakage of such patches, a not infrequent occurrence, with resultant mediastinitis and usually death when such occurred in the thorax. This, he pointed out, was quite in contrast to the neck, where the patient could live to fight another day while secondary repairs were tediously completed. It occurred to me that in severe blunt trauma to the neck with tracheal separation, the surgeon usually found that

Presented at the Twenty-fourth Annual Meeting of The Society of Thoracic Surgeons, New Orleans, LA, Sep 26–28, 1988.

Address reprint requests to Dr Grillo, Massachusetts General Hospital, Boston, MA 02114.

Fig 1. The first thoracic surgical procedure. The birth of Eve, from the facade of the Duomo at Orvieto, Italy.




the distal trachea had slipped into the thorax. I suggested that we might consider electively dropping a segment of trachea into the chest to accomplish safe intrathoracic reconstruction and complete the cervical reconstruction later. Dr Churchill accepted this with his usual tolerance for the ideas of the young, but I cannot remember that it generated much enthusiasm from anyone present.

The idea persisted. After a time it seemed to me to be worth investigating. Given the erratic and generally disastrous results of prosthetic replacement of the trachea, I

decided that any reconstruction I might attempt would be based on use of the patient's own tissues. The initial questions were as follows. First, how much trachea could one resect and still bring the ends together primarily? Second, if one really did devolve the cervical trachea into the chest, what would be the best way to reconstruct the cervical trachea?

At that time I was working in the laboratory with Dr Jerome Gross (Fig 3), in an effort to apply some of his vast knowledge of collagen and connective tissue to problems

Fig 2. The Bulfinch Building, Massachusetts General Hospital, in 1823. The Fenner-Sears print. The operating room was located under the dome. The first operation performed was on September 21, 1821. Here was made the first public demonstration of general anesthesia for surgery on October 16, 1846. The "Ether Dome" is now a conference room.



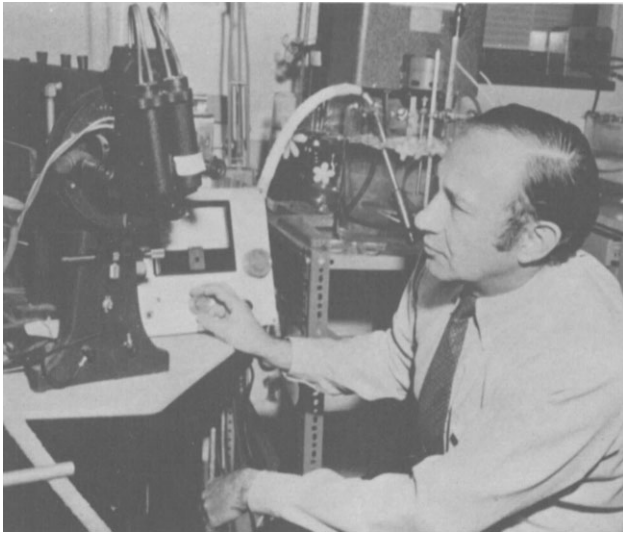


Fig 3. Dr Jerome Gross, Chief of the Lovett Laboratories, Department of Medicine, Massachusetts General Hospital. He taught and stimulated many young physicians and scientists who went on in research and clinical careers, enriched by their experience and contact with his innovative mind.

of wound repair. I mention this because I am convinced that these studies were important to me methodologically in subsequent work on the trachea. From work on the biology of wound contraction and wound collagenases, I believe I learned something about experimental methods [6, 7]. From additional work with reconstituted collagen for use as a surgical prosthetic material, I learned what one can expect from implantation of biological materials [8]. A most important lesson was that one cannot repeal the laws of wound repair. The young surgical investigator who proposes to design new operations will do well to ground himself in a thorough knowledge of tissue responses to injury and the processes of repair.

As young surgeons in those days were not deluged with patients as they seem to be today, I did find time to embark on both tracheal projects almost simultaneously. The first was to investigate in the dissecting room the potential for reapproximation of the human trachea after excision of various lengths of thoracic trachea, measuring the tensions necessary to approximate the ends and working out methods of mobilization that might ease anastomotic tension. At the same time in the experimental laboratory, we worked on methods to reconstruct the cervical trachea to close the gap that I presumed would occur when a segment of cervical trachea was devolved with its blood supply into the mediastinum. I was assisted in these efforts by two devoted young surgeons, Dr Ellen Dignan and Dr Tsuyoshi Miura from the University of Tokyo. For cervical tracheal replacement we eventually settled upon a multistaged method, using a bipediced flap of skin and underlying platysma that was splinted with polypropylene rings inserted between the dermis and platysma [9] (Fig 4).

Mobilization studies indicated that approximately one half of the human adult trachea could be removed and the

ends brought together in a predictable fashion without excessive tension [10] (Fig 5). I failed then, as so many young investigators do, to explore the literature thoroughly before embarking on the project. However, I was reassured to find later that Michelson and colleagues had arrived at similar conclusions in 1961 [11].

A question still remained. How could anesthesia and ventilation be maintained? I had early put aside cardiopulmonary bypass, believing that the anticoagulation was unwise in intrathoracic resection, in which the lung might well have to undergo substantial manipulation. This was even more the case in patients who might have limited pulmonary function. I turned for a solution of this problem to an imaginative anesthetist, Dr Henrik Bendixen, who was one of a group of anesthesiologists at Massachusetts General Hospital who developed one of the very first respiratory intensive care units in the United States. We had numerous blackboard sessions in which we worked out techniques that we would use for direct intubation across the operative field using flexible armored tubing. The guiding principle was to work out a method by which the patient would be continuously under complete ventilatory control and remain fully oxygenated, so that there would be no periods of hurry or crisis during reconstruction.

Just as we concluded these initial experiments and preparations, Dr Earle Wilkins identified a tracheal tumor as the cause of a 48-year-old woman's slowly progressive dyspnea over 5 years. She could now only breathe stridorously sitting up, leaning forward. After bronchoscopy, which demonstrated a highly obstructive lesion in what I thought was the lower trachea, obstruction worsened that evening (November 26, 1962) and the patient was hustled to the operating room. The approach was a right cervicomediothoracic trapdoor incision that would give access to the entire trachea if there was need. I was startled to find that this was not a tumor of the lower trachea at all, but a carinal "cylindroma." My thinking at that point had not yet progressed to the knotty problem of carinal reconstruction. After resection of the tumor, I looked at the three open ends of trachea and bronchi and wondered what to do next. Dr Bendixen mercifully broke the tension as he looked into the wound from the head of the table, commenting as the patient breathed in and out of the left main bronchus, "Well, that certainly does cut down on the dead space." However, on the basis of work already done, it was possible to perform reconstruction, suturing the right main bronchus end-to-end to the trachea and the left bronchus end-to-side [12] (Fig 6). My assistant was the chief resident, Harold Urschel. I am happy to say that the patient did indeed survive and lived more than 17 years before returning with recurrent carcinoma. Two further lessons about adenoid cystic carcinoma of the trachea were learned then: one was the need for follow-up for greater than 10 years, and the other was that postoperative irradiation is probably advisable even where margins and lymph nodes are negative.

I probably would have examined the question of carinal reconstruction in the autopsy room and experimental laboratory had I not been propelled by this first case into an unplanned operating room experiment. With its suc-

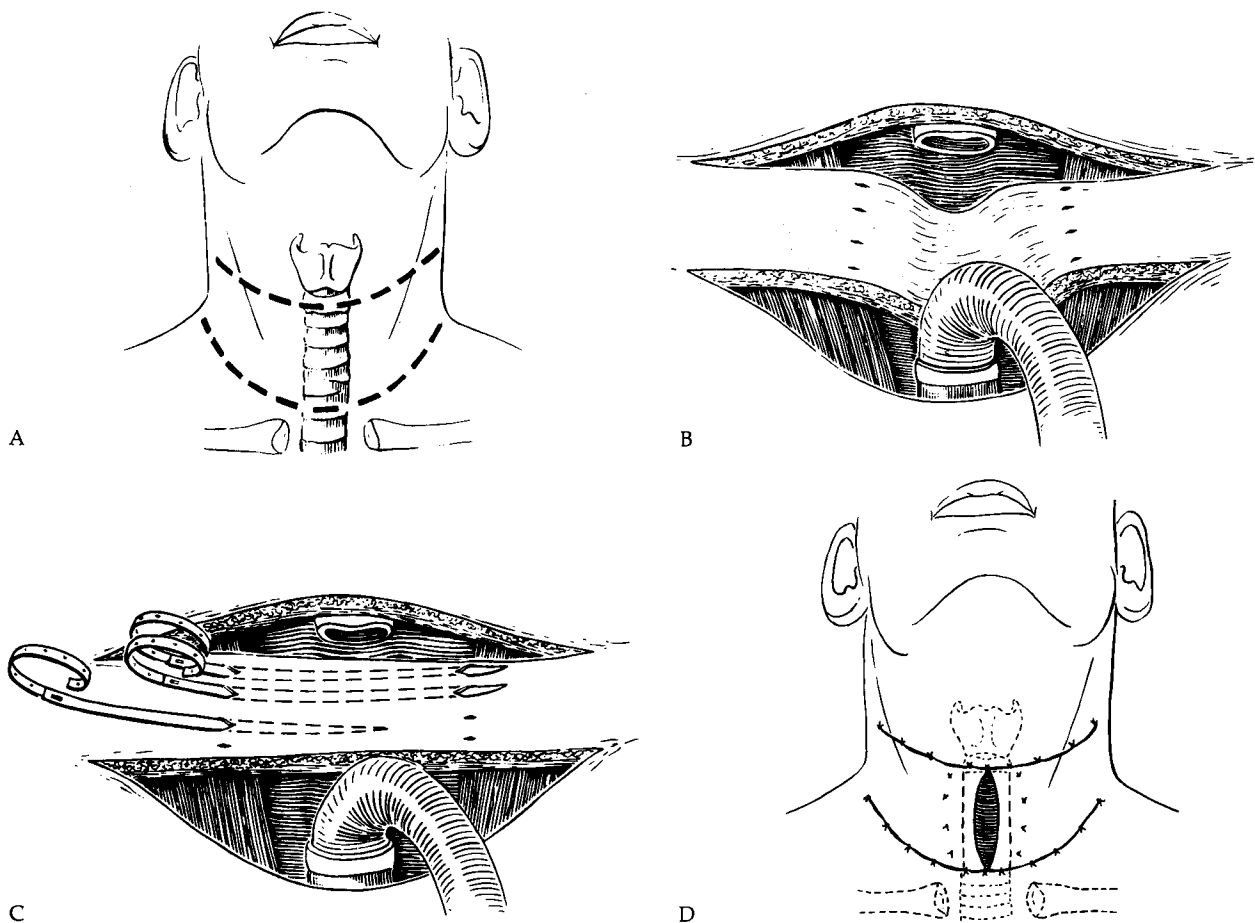


Fig 4. Cutaneous reconstruction of the trachea using skin and platysma splinted with inlying polypropylene rings. A. The bipedicled flap. B. The flap lying in the defect. C. The rings being inserted between skin and platysma. D. The interposed replacement. In a final stage, the anterior defect was closed. (Reproduced with permission from *Ann Surg* 1965;162:374.)

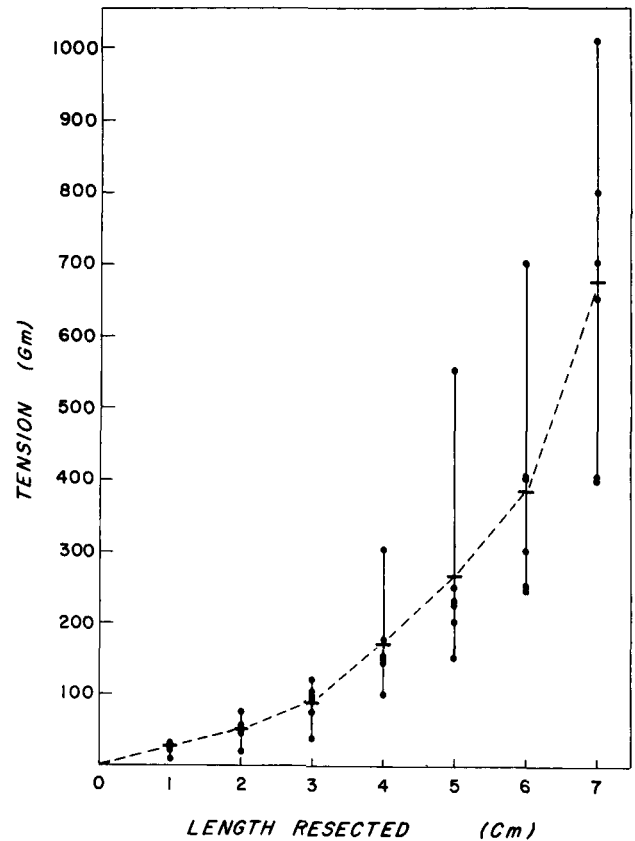
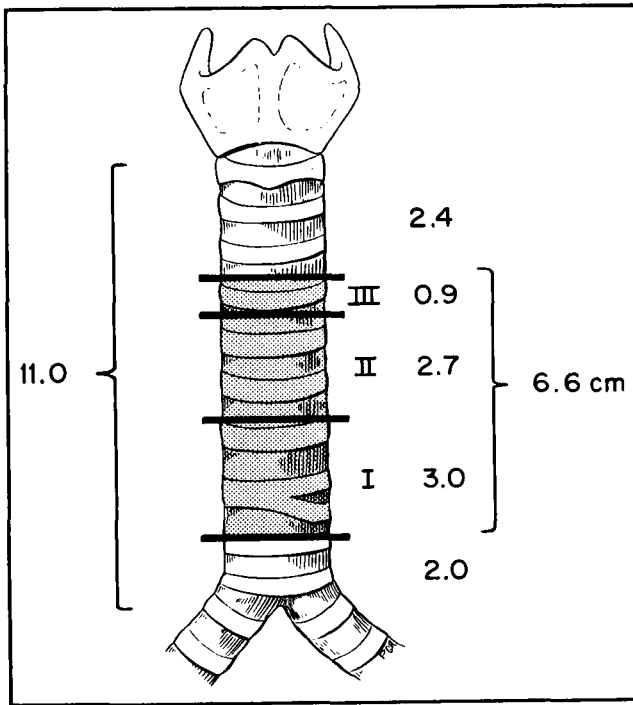
cess the development of carinal reconstructive techniques followed in the operating room, as I was secure in the knowledge that the basic elements of the operation were dependable. Gradually a systematic approach was developed for the various lesions requiring carinal resection and reconstruction [13].

I suspect that had the first case not succeeded, I might have seriously questioned the entire project. Two further successful transthoracic reconstructions for tumors followed the first case. One patient had squamous carcinoma of the lower trachea. Years later he had a lobectomy for a second squamous cancer and even later he underwent coronary bypass operation. The other had a large squamous papilloma. A few cutaneous tubes were fashioned before later information made it clear that they were rarely necessary [14].

In 1964 Dr Henning Pontoppidan of our Respiratory Intensive Care Unit introduced me bronchoscopically to the terrible destruction caused by cuffs on tubes in the trachea. I saw broken and protruding rings in the trachea of a patient who was still being ventilated. It wasn't too long after that that a patient was readmitted who had been ventilated successfully for toxic ingestion. She now had severe airway obstruction and bilateral basilar pneu-

monia. She was the first patient whom I treated surgically for postintubation stenosis (January 1965) (Fig 7). Her recovery was uneventful [14]. I would now be critical of treating a patient in this way. Today, she would have her stenosis dilated, the pneumonia would be cleared with medical treatment, and then elective resection would be done. Further, resection would be done from the anterior approach without opening the pleura.

A number of patients appeared with stenotic lesions of the trachea after intubation and ventilation. Many lesions were in the upper trachea. Stomal stenosis was recognized and differentiated from cuff stenosis. It was clear that the work that we had done on mobilization in the chest had little pertinence for these patients. I therefore returned to the dissecting room aided by Dr John Mulliken, a surgical resident. We selected an approximation tension (1,000 to 1,200 g) that was within what seemed experimentally to be a safe level and then determined, with the patient's neck in flexion (15 to 35 degrees), what length of trachea might be removed [15]. As a fall-back position might be necessary, we added to this the amount that might be gained additionally by intrathoracic mobilization, if the ends could not otherwise be brought together safely (Fig 8). This was somewhat theoretical as



A. Diagram of the average amount of trachea that can be removed by steps in mobilization and still permit end-to-end anastomosis. I. Right hilar dissection and division of pulmonary ligament. II. Division of left main bronchus at carina and reimplantation. III. Dissection of pulmonary artery and veins from pericardium. In actual clinical use the right hilar dissection was followed by intrapericardial mobilization. Only rarely was the drastic step of bronchial reimplantation used, in view of the potential for complications. (Reproduced with permission from *Ann Surg* 1965;162:374.) B. Tension required for approximation after removal of successive segments of trachea. (Reproduced with permission from *J Thorac Cardiovasc Surg* 1964;48:741.)

many patients who had postintubation strictures had poor pulmonary reserve and would not tolerate transthoracic procedures. The approximation afforded by cervical flexion even greater than this also made cutaneous tube reconstruction unnecessary.

It is embarrassing to admit that it was only in connection with mobilization of the upper trachea that I realized how much cervical flexion could contribute to intrathoracic tracheal resection and reconstruction. The obvious is often only obvious after you have recognized it. Later I used the adjunct of laryngeal release for upper tracheal reconstruction, borrowing this from the otolaryngologists, moving from the thyrohyoid release of Dedo and Fishman [16] to the suprahyoid release of Montgomery [17]. It became evident that close communication with otolaryngology was necessary as the airway surgeon moved upward in the trachea. Disease does not tidily respect our anatomical and jurisdictional boundaries.

A gratifying aspect of this early work was my meeting a Canadian thoracic surgeon who also had strong interests in the trachea at the meeting of the American Association for Thoracic Surgery in Montreal in 1964. Up to that time I had the feeling that I was working in something of a

professional vacuum. Almost no one in thoracic surgery seemed the least bit interested in the problems of airway surgery. It was a delight therefore to find that Griff Pearson was working actively with these same problems (Fig 9). Through subsequent years we developed a close relationship and always spoke freely and extensively of our observations, problems, and solutions to matters involving the trachea. I gained a great deal from this interchange. I hope it was mutual. We even managed to extend these seminars to include a few trout fishing expeditions. In casting a trout fly there is no question that I was the pupil.

Postintubation stenoses rapidly became the dominant group of cases. They came from all over, requiring only that patients survive ventilator therapy and that the diagnosis be made. There was considerable confusion and no shortage of theories about the origin of these lesions. It was essential to understand the pathogenesis of the lesions if we were to make any headway in their prevention. As a first step, I elected to look at the trachea of every patient who had been on a respirator who reached the autopsy room. Fortunately, the surgical resident assigned to pathology was a bright young man who eagerly ac-

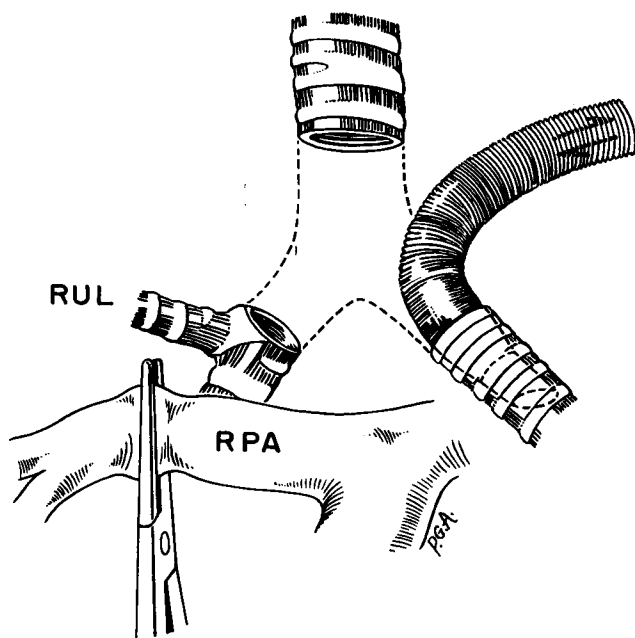


Fig 6. Our first tracheal reconstruction, which proved to be carinal. Reconstruction was accomplished by suturing the right main bronchus to the trachea and implanting the left main bronchus into the low lateral trachea. Temporary occlusion of the right pulmonary artery (RPA) eliminated perfusion of the unventilated lung. (Reproduced with permission from *Ann Surg* 1963;158:889.)

cepted my proposal that he take on this project with me. In no time at all he did a superb job of collecting and ordering these specimens (Fig 10). We developed an episodic, but complete picture of the pathological evolution of the injuries, concluding that the most important factor in etiology was pressure necrosis [18] (Fig 11). That promising young resident was Joel Cooper (Fig 12).

Our observations confirmed and extended like observations in Europe [19] and correlated with clinical observations [20, 21]. An interesting sidelight is that these lesions had gone largely unnoticed by pathologists. It is an example of the trap that we see what we expect to see. More positively, it is an example of how surgery repays its debts to anatomy, physiology, and pathology. The surgeon's project-oriented approach seeks specific information about a defined problem, often for a pragmatic goal. In so doing we make observations less likely to be made by our colleagues in other disciplines who view a system, an area, or a disease more generally.

An earlier example of this same motivation was our need to know the blood supply of the cervical trachea. When Dr Miura and I turned to the anatomy books, information was scant. We therefore did a series of injection studies that defined the patterns of blood supply to the upper trachea from the inferior thyroid artery [22] (Fig 13). Later, Salassa, Pearson, and Payne [23] completed a classic study of tracheal blood supply.

Dr Cooper and I decided to reproduce postintubation stenosis lesions, if possible, in an experimental animal, in part to confirm the thesis that pressure necrosis was the single most important cause of tracheal erosion and sub-

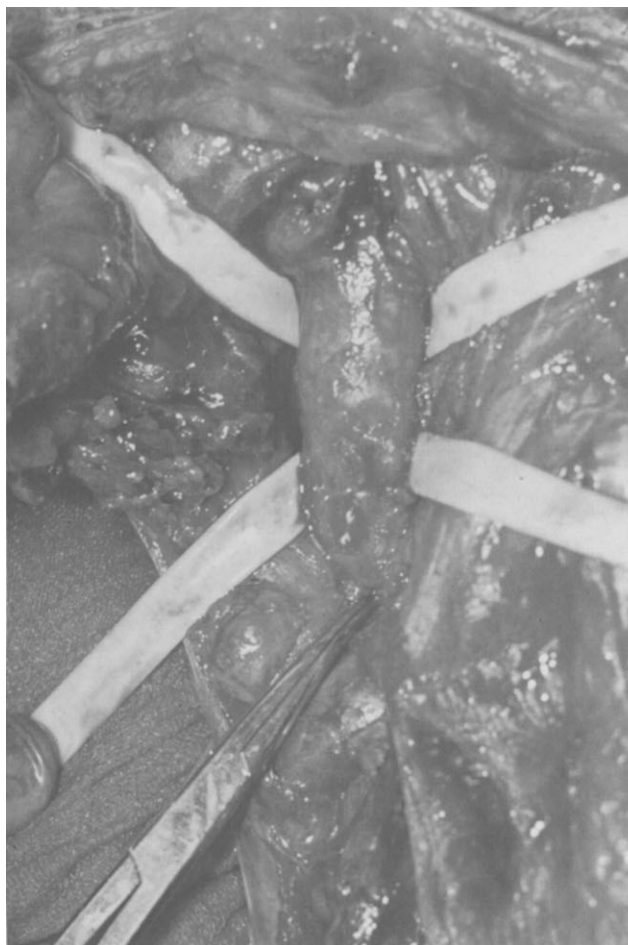sequent stenosis but also to provide a model that might be used to study methods of preventing the lesions. The lesions were reproducible. Indeed, experimental dogs incurred these lesions in 100% of cases (Fig 14), just as they responded to our concept of a low-pressure, large-volume cuff in 100% of cases [24] (Fig 15).

It is an interesting commentary on the initiative of industry that it took more than a year to find a company willing to embark on production of a low-pressure cuff. Once this cuff had been produced and its safety proved, a randomized series of patients soon demonstrated clearly that our low-pressure cuff eliminated tracheal cuff stenosis [25] (Fig 16). This model was one of the prototypes of the cuffs that we all now use. The original cuff was made of latex which, because of extension characteristics, simply does not produce cuff injury. Ironically, it is no longer manufactured because of cost considerations having to do with shelf life and bonding of latex to plastic. Hence, all cuffs currently in use are plastic. These are usually safe when used as directed, but because attendants do not always follow directions and because the extension characteristics of plastic are different from latex, tracheal stenoses continue to be produced due to overinflation. These serve to teach residents the techniques of tracheal resection and reconstruction.

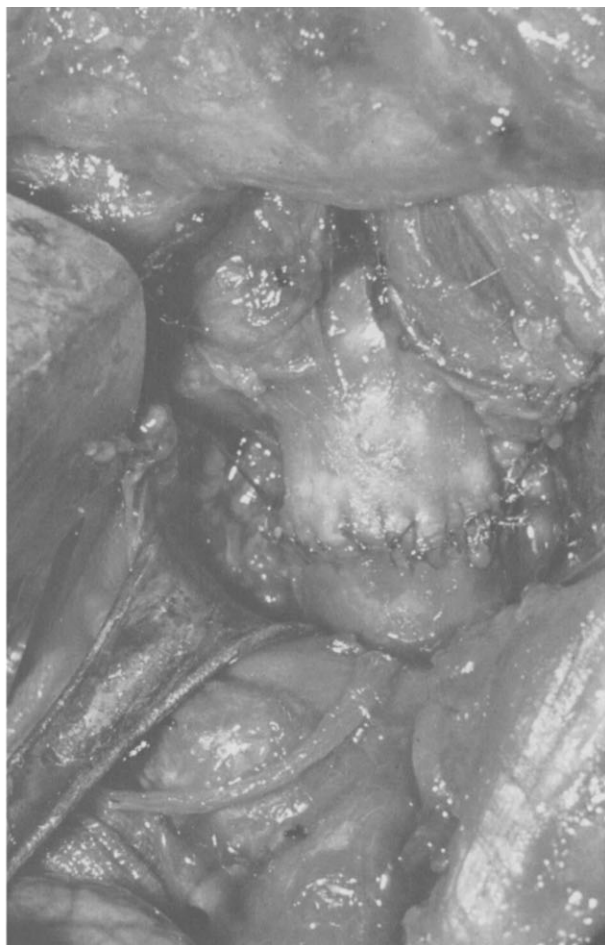
I like to think there may have been another benefit from these experiments. It is presumptuous for a teacher to take credit for a pupil's innate abilities and industry. I do, however, take considerable satisfaction in the fact that this work was Joel Cooper's introduction to research and, if nothing else, may at least have "hooked" him in the way of the investigator.

I began to see children with tracheal stenosis. I was uncertain whether the techniques developed in adults would work equally well in children. Although parallels could be drawn with coarctation of the aorta and bowel repair, the questions were unanswered whether tracheal anastomosis in infancy would grow proportionally with the child and whether delicate juvenile tissues would withstand tensions used in adult tracheal surgery. With the meticulous and painstaking help of Dr Masazumi Maeda, then from the University of Osaka and now professor of surgery at Kagawa University, and Dr Yahiro Kotake, these problems were analyzed in puppies. The facts that emerged were of practical use. First, the anastomoses, if done properly, did grow to 80% of normal [26]. Second, the juvenile trachea withstood tension less well than that of the adult [27] (Fig 17). We also explored methods that could be used to diminish tension [28]. This information was applied clinically [29]. A general rule may be enunciated that the average adult trachea can withstand resection of approximately one half of its length, but the juvenile trachea can withstand resection of no more than a third before problems based on tension may occur.

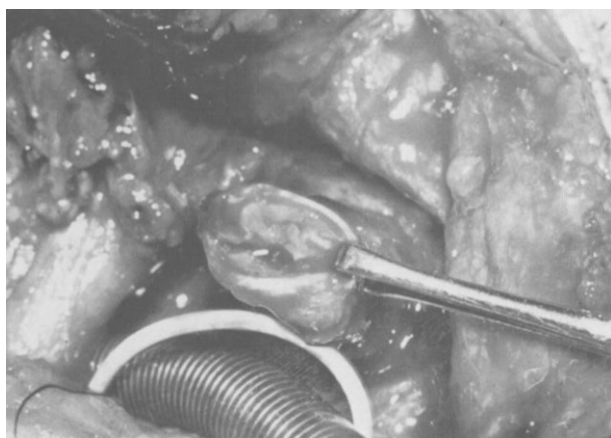
I shall not prolong what would become a tedious recital of the many tracheal problems with which we have attempted to deal. We should consider, however, that 30 years ago a lecture on tracheal surgery would have consisted largely of a description of the problems of tracheostomy with a few comments on ad hoc solutions to



A



C



B

Fig 7. Our first resection and reconstruction for postintubation stenosis. A. The lesion isolated. B. The end of the stenotic segment visible. Intubation is across the field into the distal trachea. C. The completed anastomosis. (Reproduced with permission from J Thorac Cardiovasc Surg 1969;57:52.)

the difficult matter of rare tracheal tumors. Now there is almost too much to discuss. Let me simply enumerate some of the problems that appeared over the last decades and note where we stand in their management. Most of these problems were not taken to the laboratory. They were seen clinically, and the solution lay in the operating room, using principles of tracheal surgery that by now

had become established. This illustrates a general course of surgical development. Once basic principles are established and their application worked out, extensions may safely follow without always needing to recapitulate prior experimental work.

Evolution of techniques of carinal reconstruction has already been noted [13]. These were systematically de-

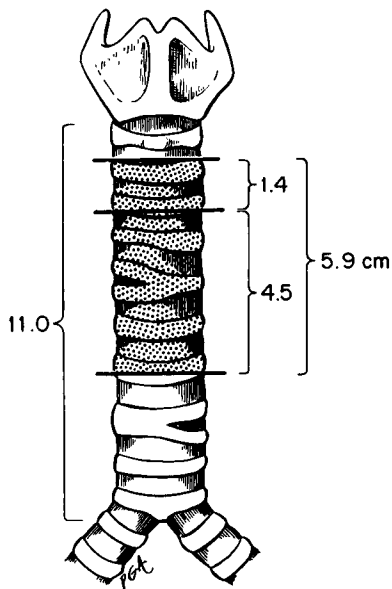


Fig 8. The amount of upper trachea that can be resected and still permit primary anastomosis under 1,000 to 1,200 g of tension was found to be 4.5 cm. Intrapericardial dissection added an additional 1.4 cm. (Reproduced with permission from *J Thorac Cardiovasc Surg* 1968;55:418.)

scribed in 1982 (Fig 18). Prior to that, in 1978, experiences with management of 28 patients with tracheal tumors, primary and secondary, offered hope for long-term survival with adjunctive irradiation even in patients with squamous carcinoma and adenoid cystic carcinoma of the trachea [30]. By 1987 127 primary tumors and 48 secondary tumors had been resected. Follow-up study is now in progress.

The other major area of tracheal reconstructive surgery was updated in 1979 with a detailed report of the types of lesions resulting from ventilation, the selection of treatment, techniques, and results, with overall good or satisfactory results in 93% of 203 patients [31]. By 1988 the number of postintubation patients resected was greater than 400. It is somewhat discouraging that these lesions continue to be seen despite the early acquisition of so much information on their prevention.

Tracheoesophageal fistula that occurs from erosion by a high-pressure cuff through the apposed membranous tracheal wall and the anterior wall of the esophagus usually occurs in conjunction with a foreign body, namely a feeding tube, in the esophagus. The common wall is pinched between the esophageal tube and a tracheal cuff. Consideration of the pathology and response of the tissues cautioned withholding repair until the patient was off the respirator. Single-stage repair with interposition of normal tissue between the two suture lines followed [32] (Fig 19). Equally important is the prevention of fistulas by avoiding prolonged use of foreign bodies in each of the adjacent aerodigestive tubes.

Tracheoarterial fistulas, caused either by erosion of a high-pressure cuff or tube tip through the anterior wall of the trachea into the innominate artery or, more commonly, by erosion by a tracheostomy tube lying against

the innominate artery due to a low tracheostomy, are managed by the excision of the affected artery and appropriate management of the trachea depending on which of the two etiologies is involved [33]. Again, the emphasis is on avoidance. A properly placed tracheostomy (at the level of the second and third rings) will not produce these fistulas.

The very difficult problem of subglottic stenosis, which affects the subglottic portion of the larynx as well as the upper trachea, has been managed with considerable success by a single-stage operation [34] (Fig 20), not dissimilar to that pioneered by Couraud and associates in Bordeaux [35] and by Bryce, Pearson, and associates in Toronto [36, 37]. Thus, the thoracic surgeon has invaded the domain of the otolaryngologist, but only because the multiplicity of often multistaged procedures previously used for these lesions has failed to give acceptable results.

The complications of tracheal surgery and their prevention were discussed in detail in 1979, with the invaluable assistance of Drs Piero Zannini and Fabrizio Michelassi [38]. This analysis provided a sound guide to reduction in incidence of complications as well as to their treatment. Dr Luciano Landa presented our experience with the use of Montgomery's T-tube in tracheal surgery [39].

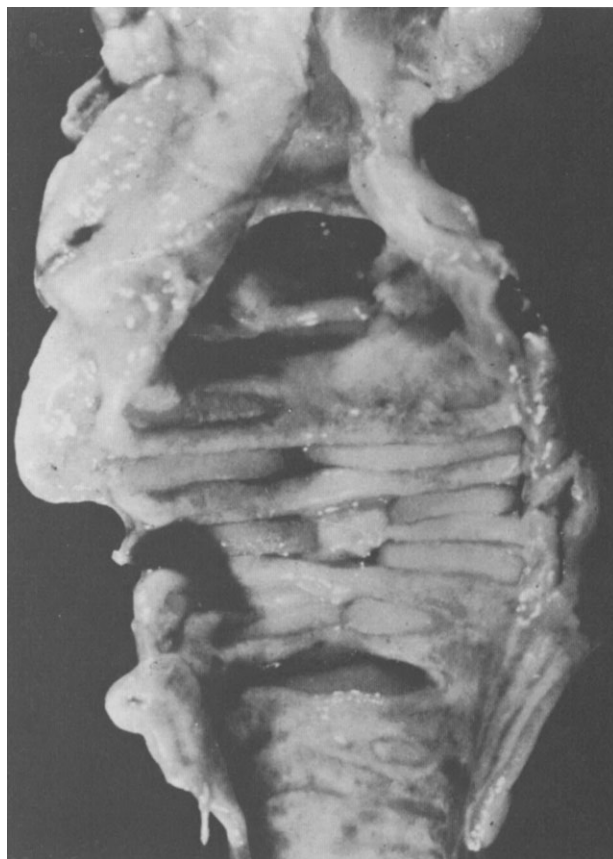On rare occasions, either for potential cure or for


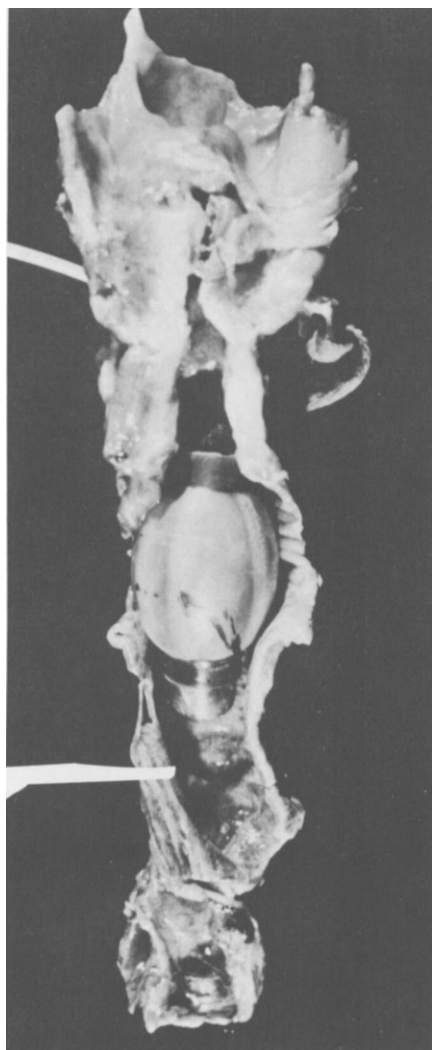


Fig 9. Dr F. Griffith Pearson, the first head of the Division of Thoracic Surgery, Toronto General Hospital. His approach to tracheal surgery was systematic, and he made special contributions to understanding the etiology and the surgical management of postintubation lesions.



A



B

Fig 10. Postmortem specimen showing severe damage at the site of the high-pressure tracheal cuff. (Reproduced with permission from *Ann Surg* 1969;169:334.)

palliation in long-standing lesions, cervical mediastinal exenteration is necessary. This consists of the en bloc removal of larynx, trachea, pharynx, esophagus, and thyroid into the upper mediastinum with, most often, reconstruction of esophagus with stomach or colon and establishment of a mediastinal tracheostomy after partial removal of the sternum. The principle was established long ago that the surface must be brought down to the stump of the trachea because there is no way that the trachea can be pulled up to the normal surface contour of the body. Drs William Waddell and Bradford Cannon at the Massachusetts General Hospital devised a method of crossed skin flaps to produce a tube that reached the trachea [40]. Nonetheless, hemorrhage continued to be a troublesome and often lethal complication in cases in which healing was not perfect. I initially attempted to solve this problem by simplifying the approach, using a large bipediced flap of skin dropped into a mediastinum that had been made accessible by removal of a bony plaque superiorly and anteriorly [41]. Despite initial success this technique proved still to be subject to the

complication of major hemorrhage. This seems now to have been solved by selective division of the innominate artery under operative monitoring after appropriate pre-operative study, and by bringing the omentum substernally into the mediastinum and neck to protect the arteries and esophageal closures [42] (Fig 21).

An unsolved problem of airway surgery, namely, resection and reconstruction of an airway that has previously received high-dose irradiation, has been similarly approached. Although this problem is not completely solved, in 6 of 7 patients in whom omentum was brought up to provide neovascularization and fibrogenesis after remote irradiation, healing has been attained. Formerly I would not have dared to operate on these patients.

During these decades surgeons have carefully extended the role of tracheal resection to some secondary tumors. Notable has been the use of carinal resection with pneumonectomy pioneered by Robert Jensik and associates [43] for selected patients with bronchogenic carcinoma. We have done our share of these and have advocated reimplantation of the lower lobe where possible. I have

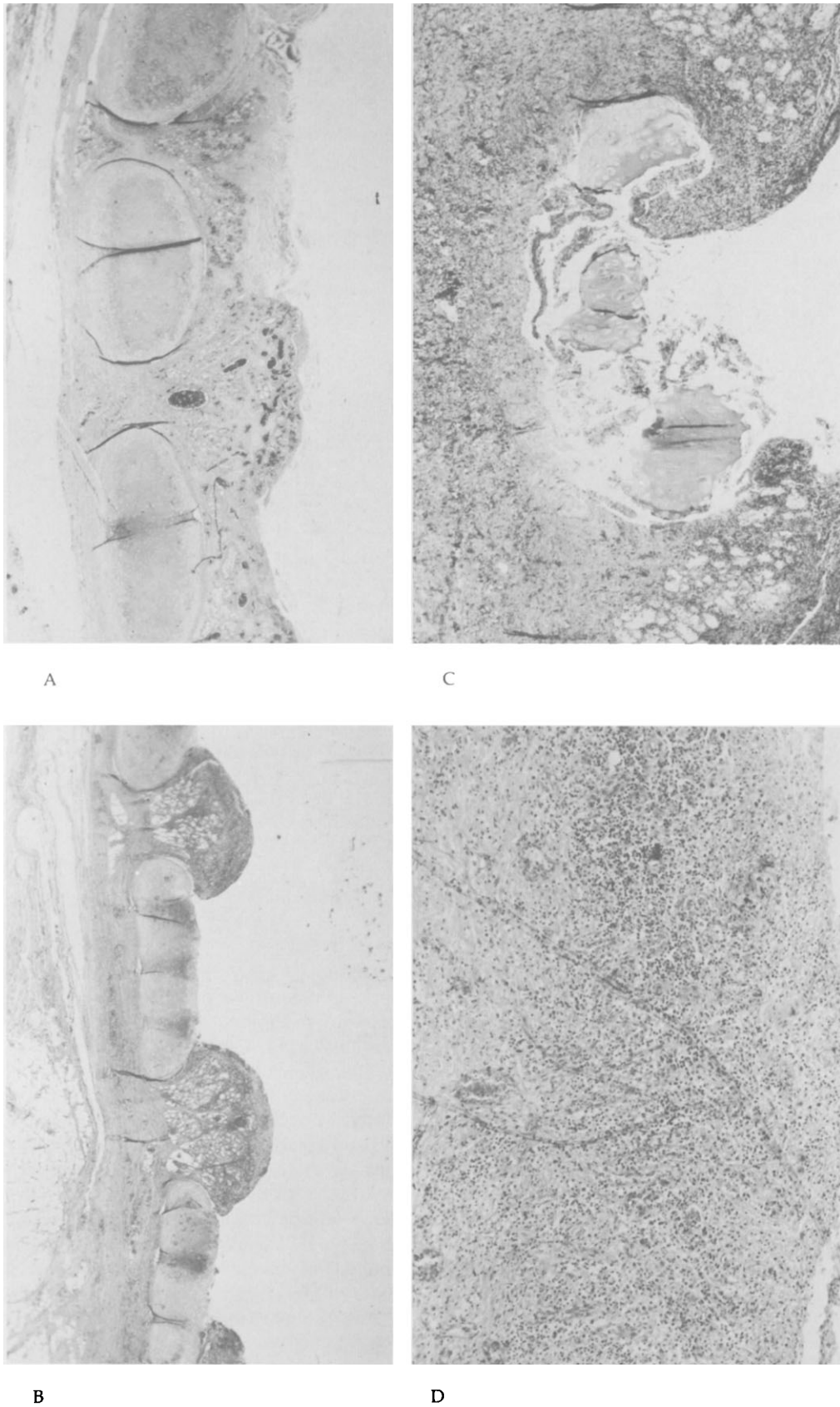


Fig 11. Microscopic study of the evolution of tracheal destruction under cuff pressure. A. Damage of the mucosa. B. Erosion to the cartilaginous surface. C. Cartilaginous destruction. D. Tracheal wall replaced by inflammatory granulation tissue.

also believed for some time that the surgeon who treats thyroid neoplasia, particularly locally invasive differentiated carcinoma in the older patient, has stopped short of fulfilling the basic tenet of treatment—removal of all local disease to prevent airway obstruction. Removal of the lower portion of the larynx and upper trachea in such cases has given promising results [44] (Fig 22). Optimal results are obtained in patients in whom such an operation is done initially or soon after the first operation. Unfortunately, this is often not the case. The airway surgeon must extend his work into areas that are not ordinarily the domain of the thoracic surgeon. The thoracic surgeon is best prepared to handle the total problem. Perhaps it is a caution against well meaning suggestions to truncate the general surgical background of thoracic surgeons. I say this not only with regard to the ability of the surgeon to accomplish specific procedures, but also because the evolution of general thoracic surgery in the future is unknown. I believe this anecdotal story of the recent evolution of tracheal surgery documents not only the specific value of an education in general surgery, but, to cite a caution by Edward Churchill, the value of a general education in surgery [45].

It is not unexpected in a Presidential Address that respectful obeisance be made to one's personal demi-



Fig 12. Dr Joel D. Cooper. After residency and fellowship at the Massachusetts General Hospital, Dr Cooper went to the Toronto General Hospital, where he succeeded Dr Pearson as head of the Thoracic Surgical Division. There he pioneered successful lung transplantation. He now heads the Thoracic Surgical Division at Barnes Hospital, St. Louis.

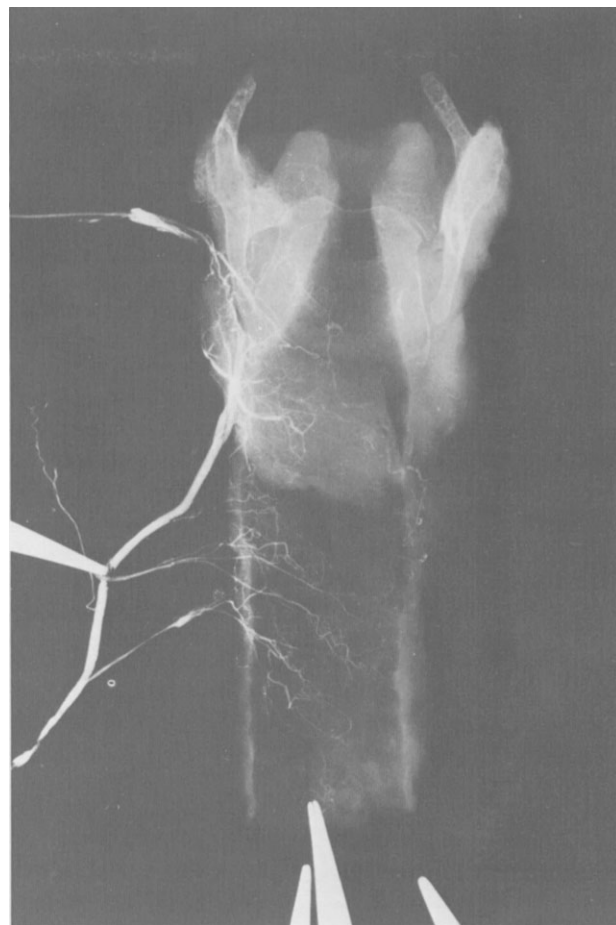


Fig 13. The blood supply of the upper trachea, demonstrated in roentgenograms of dissected specimens with barium sulfate injection of the inferior thyroid artery. (Reproduced with permission from *Surg Gynecol Obstet* 1966;123:99.)

gods—great teachers. I've spoken of Edward D. Churchill (Fig 23), truly one of the founders of thoracic surgery, great in his conceptions and in his surgical and pedagogical accomplishments, to whom I owe great debts, direct and indirect [46-49]. Richard H. Sweet (Fig 24), perhaps the all-time master of esophageal surgery, provided another model. None who observed his surgery hoped to equal it, but his elegance and precision were the standards to which we aspired [50].

Throughout all of this work it has been a particular pleasure to enjoy the fellowship of a relatively small number of thoracic surgeons around the world who are profoundly interested in the trachea. I have already mentioned my relationship with Dr F. Griffith Pearson. I particularly wish to acknowledge the outstanding contributions by Mikhail Perelman of Moscow (Fig 25) and Henri Eschapaspe of Toulouse (Fig 26). Exchanges of opinion with these superb and innovative surgeons have been most valued over many years.

Surgical efforts are always intertwined with other disciplines. Each contributes to the other's development. Thus, as tracheal work evolved, Benny Geffin and then Roger Wilson took on the problems of anesthesia in

Fig 14. Experimental production of tracheal erosion from standard high-pressure cuffs in the canine trachea. At seven days the lesions mimicked those seen in humans. (Reproduced with permission from Surg Gynecol Obstet 1969;129:1235.)

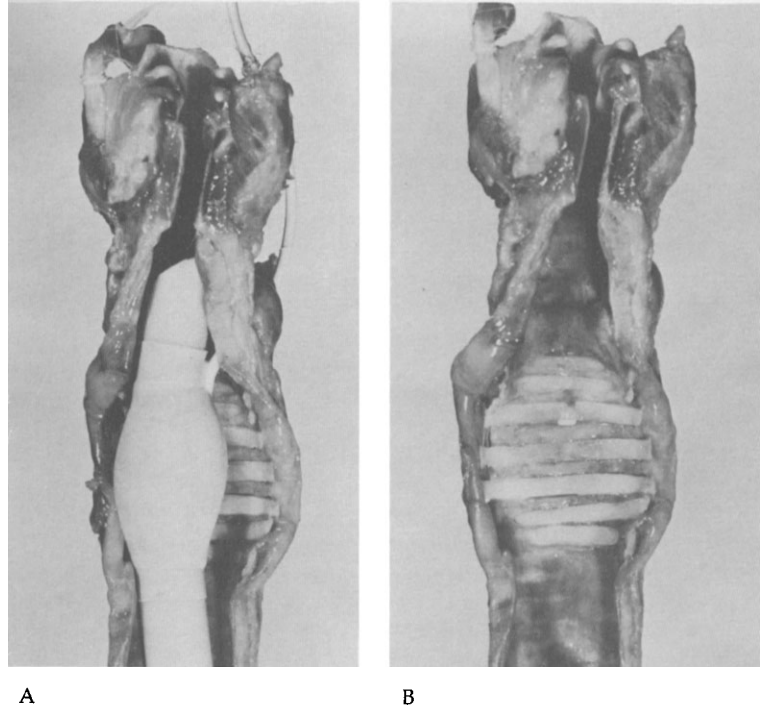
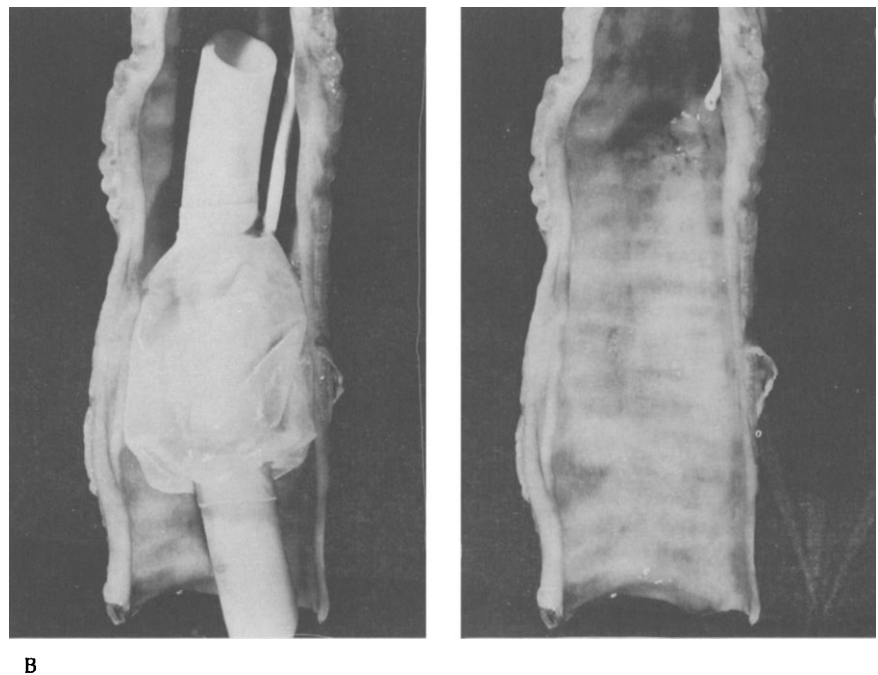
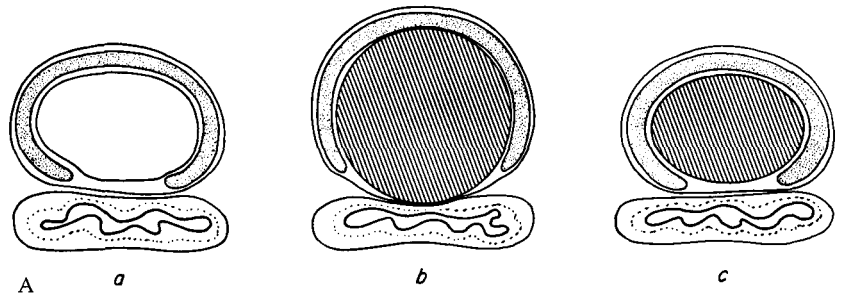
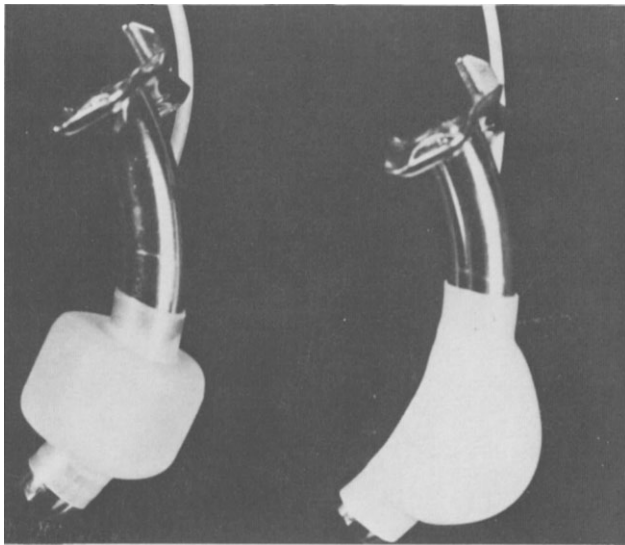
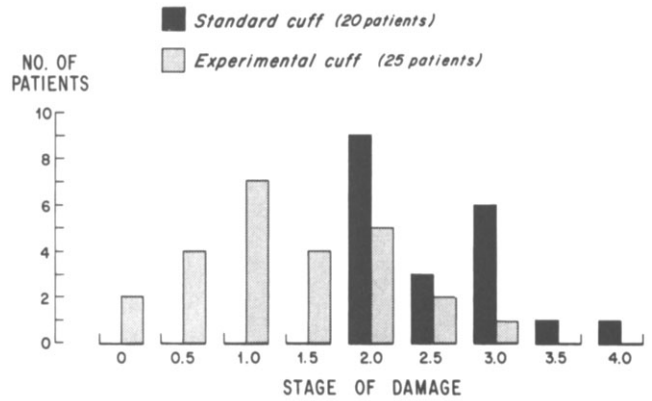


Fig 15. A. (a) Diagram of the sealing of the trachea by a high-pressure cuff (b), which has deformed the trachea as it expands to occlude the lumen, and by a low-pressure cuff (c), which has flowed out to conform to the tracheal lumen and seal it before the pressure rises. B. Appearance of the dog's trachea (right) after 13 days of exposure to a large-volume, low-pressure balloon cuff (left). (Reproduced with permission from Surg Gynecol Obstet 1969;129:1235.)





A



B

Fig 16. A. The experimental latex large-volume, low-pressure cuff (left) compared with a standard Rusch cuff (right), both mounted on standard Jackson tracheostomy tubes. B. Damage to the human trachea from standard high-pressure and experimental low-pressure cuffs. The slight degrees of damage seen with the low-pressure cuff were not in ranges that led to stenosis. (Reproduced with permission from *J Thorac Cardiovasc Surg* 1971;62:898.)

tracheal surgery [51, 52]. If there is any area of surgery in which the anesthetist and surgeon must be in close and continuous communication, this certainly is it. Residents in anesthesia at Massachusetts General Hospital look forward to their rotations on thoracic surgery in part to deal with complex intrathoracic airway reconstructions. Two radiologists at the Massachusetts Eye and Ear Infirmary, first Dr Alexander McMillan, Jr, and then Dr Alfred Weber, standardized and simplified the radiology of the larynx and upper trachea in a way that defines the lesions precisely without the necessity for contrast or exotic studies [53, 54]. Dr Theresa McCloud and her associates have carried on a similar characterization of the lower trachea and carina [55]. Obviously there are parallels also in the work of the pulmonary pathologist Dr Eugene Mark [56] and of our pulmonologists [57]. These are examples of the web that exists in all of our therapeutic efforts. No one would dare to undertake carinal reconstructions without the support of an expert nursing service and intensive care unit staff as well as these other specialists.

I must state the obvious—not all problems of airway surgery are solved. Two in particular are insistent. The first is that of subtotal replacement of the trachea. With the techniques that have evolved, a need for subtotal replacement arises in only a very few patients in a year. The key example is that of a longitudinally infiltrating adenoid cystic carcinoma without extensive mediastinal or laryngeal invasion. Although episodic successes have been reported with a variety of foreign prostheses from the beginning of tracheal surgery [4], most still founder on a biological reef. When foreign material is implanted into the body in contact with an epithelial margin, a chronic nonhealing ulcer results. The usual results are, after a time, obstruction due to chronic granulations or erosion of major blood vessels with fatal hemorrhage. None of the prosthetics currently available have triumphed over these problems to a degree that makes them safe in general usage. It is particularly the case in the lengthy resections for which they are truly needed. A new concept is required. All currently successful surgical prosthetics

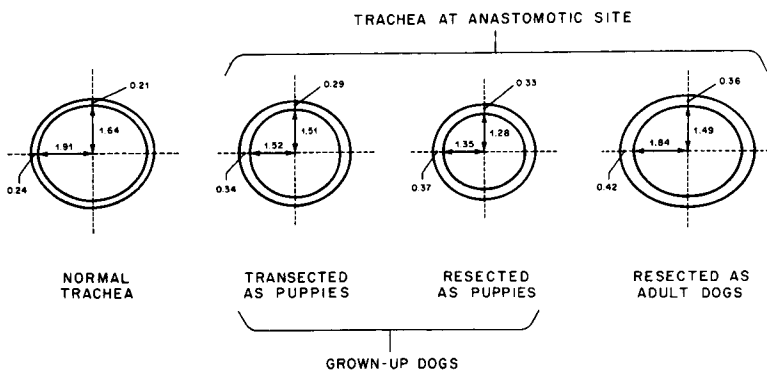


Fig 17. Tracheal cross-section measured at anastomotic sites in the normal adult dog, in dogs transected as puppies and in dogs who underwent resection as puppies (at the grown-up stage in both), and in dogs with resection as adults. These studies demonstrated that the juvenile trachea grew satisfactorily, but was influenced by the tension resulting from resection. (Reproduced with permission from *J Thorac Cardiovasc Surg* 1973;65:658.)

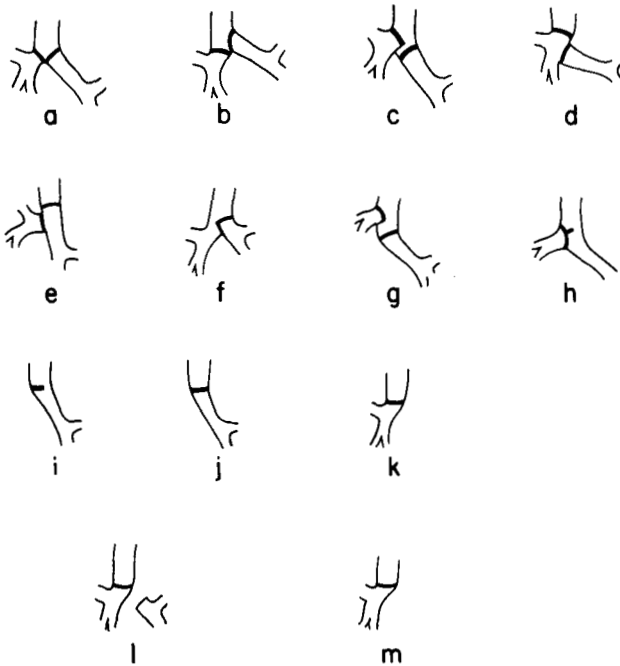


Fig 18. Types of primary reconstruction performed in the first 31 carinal resections. (Reproduced with permission from *Ann Thorac Surg* 1982;34:364.)

(vascular, cardiac, and orthopedic) are embedded in mesenchyme, which is potentially sterile. There are no examples of prosthetics that are usually successful in the gastrointestinal tract, the genitourinary tract, or the respiratory tract.

Important also is the dependability of any technique. This is illustrated by the efforts a few years ago by Dr Joo Hyun Kim and I to create a complex prosthesis with the following characteristics: (1) a rigid tube, (2) autologous tissues, with good blood supply, (3) epithelial surface, and (4) anatomical mobility. In dogs we constructed a tube that consisted of a cylinder of cartilage formed from costochondral perichondrium wrapped around a stent. The epithelial lining of the tube was a buccal mucosal graft. The tube, constructed in stages, was based on an intercostal pedicle, which allowed it to be moved into the tracheal defect. It worked just fine in *some* of our experimental animals. On the other hand, more experiments

Fig 20. Subglottic stenosis involving the lower larynx and upper trachea. A. The lesion. B and C. Resection includes the anterior subglottic larynx and the scarred mucosa overlying the cricoid plate. D. In the reconstruction, the flap of membranous wall resurfaces the cricoid plate and the cartilaginous trachea reconstructs the subglottic larynx. (Reproduced with permission from *Atlas of General Thoracic Surgery*, Ravitch M, Steichen F, eds. Philadelphia: WB Saunders, 1988.)

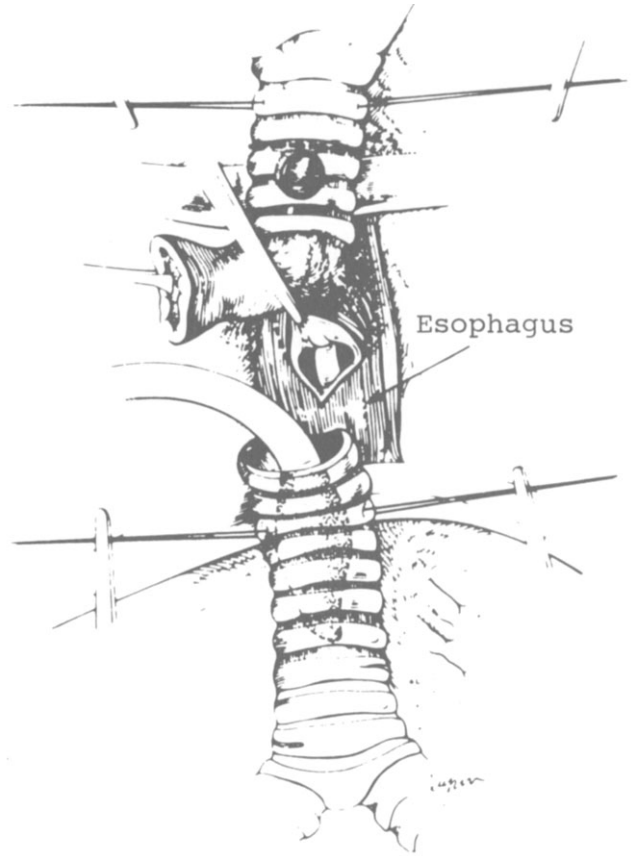
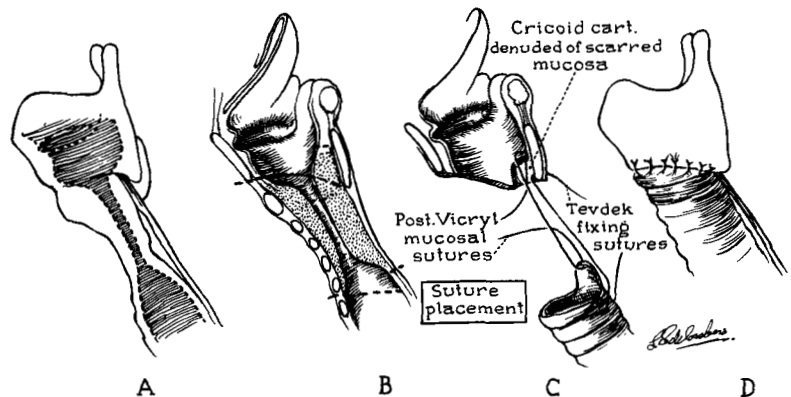


Fig 19. Single-staged repair of acquired tracheoesophageal fistula. The damaged tracheal segment is resected with the fistula. The esophagus is closed in layers, and strap muscle is interposed between it and the subsequently anastomosed trachea. (Reproduced with permission from *Ann Thorac Surg* 1976;22:112.)

failed than succeeded. Clearly this is not a procedure that one would ever attempt in humans. Indeed, we refrained from publishing the results despite the intriguing successes achieved. It is an old belief of mine that when 100% of experiments in animals succeed, there is a bare possibility that the procedure may work in humans. As the percentage of success in the experimental animals drops, the likelihood of a complex method succeeding in humans becomes remote.

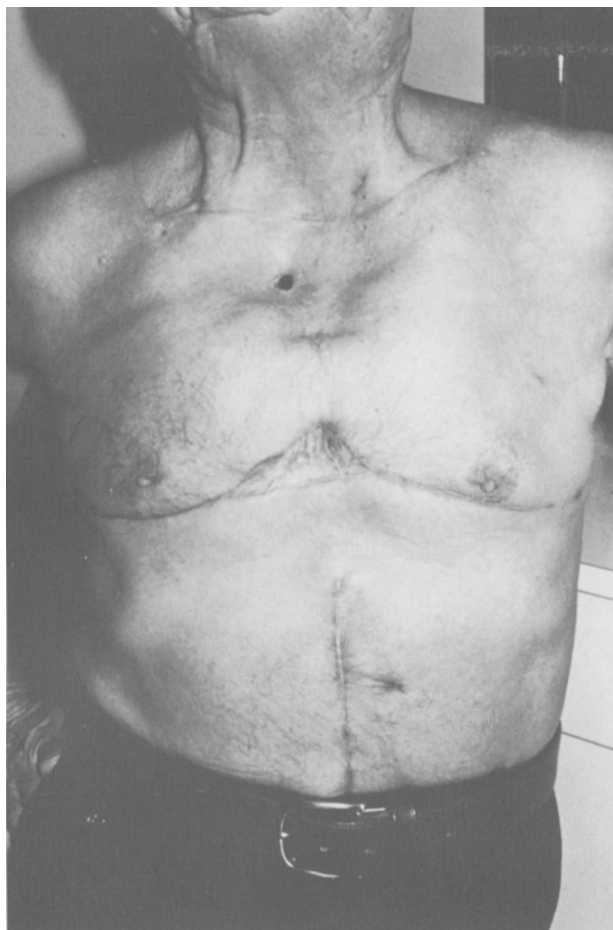

Fig 21. The final result from cervicomediastinal exenteration with mediastinal tracheostomy. The parallel incisions along the line of the clavicle and below the breasts are visible. The sternal defect may also be seen, with the end tracheostomy lying within the mediastinum. The colon or stomach and the omentum are advanced substernally.

Another broad area of work in progress is treatment of what may loosely be catalogued as tracheomalacia. This includes a variety of malacic changes in the trachea, such as idiopathic diffuse loss of cartilage, expiratory collapse with broadening of the rings and membranous wall, and segmental malacia in postpneumonectomy syndrome. We have handled these and other cases surgically in numerous ways including the use of posterior splinting of the elongated membranous wall following the methods of Nissen, Herzog, and associates [58, 59], the use of circular polypropylene splints in patients with tracheomalacia due either to idiopathic causes or to compression by goiter, and a variety of procedures for the intriguing and complicated entity of airway obstruction following mediastinal displacement after right pneumonectomy (and its mirror image of left pneumonectomy with right aortic arch) [60]. There is much left to be done by the young surgeon interested in difficult problems of the airway.

What lessons may be learned from this surgical odyssey? Perhaps the lessons are largely a reaffirmation of platitudes. Our learning process in life is continuous.

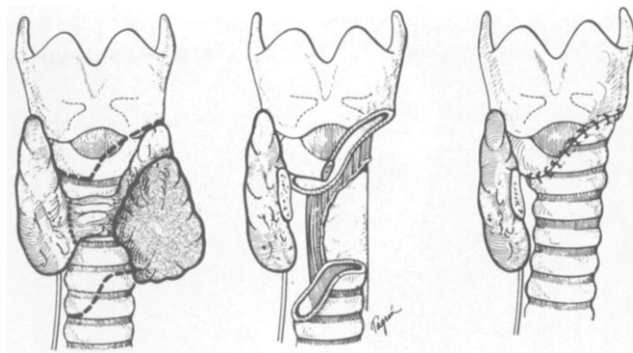


Fig 22. Aggressive local resection of differentiated thyroid carcinoma invading the airway. A portion of the lower larynx as well as the upper trachea has been excised with the tumor. Recurrent nerve was already paralyzed by the lesion on that side. The trachea is tailored to fit the laryngeal defect. A portion of esophageal muscular wall has also been removed. (Reproduced with permission from *Ann Thorac Surg* 1986;42:287.)

Experience sometimes heightens awareness of the true meaning of conventional wisdom previously accepted on an intellectual basis. Concepts then become something that we know with real understanding. I shall recite a few



Fig 23. Dr Edward Delos Churchill (1895-1972), John Homans Professor of Surgery at Harvard and Chief of the Surgical Services, Massachusetts General Hospital, pioneer in thoracic surgery, outstanding surgical educator, and a surgical scholar and humanist.



Fig 24. Richard Harwood Sweet (1901-1962), Associate Clinical Professor of Surgery at Harvard and Visiting Surgeon at the Massachusetts General Hospital, a master surgeon who, with Churchill, pioneered modern esophageal surgery. He reported clinical experience precisely and was an invaluable teacher for the resident surgeon and a founder of the Board of Thoracic Surgery. Photographed by Fabian Bachrach.

of these platitudes, perhaps better dignified as principles. (1) There must be a willingness to question and to reexamine conventional wisdom. Examples I gave at the outset were those of the "2-cm rule" for tracheal reconstruction and the often repeated statements that cartilage did not heal. The questioning must apply to one's own assumptions also. (2) An experience in scientific research, even in a remote discipline, helps to prepare the clinician for an analytical approach to problems. I hurry to add that the young surgeon must desire and seek such an experience. I do not believe that enforced labor in the laboratory will be productive or even educational. (3) Careful laboratory preparation to the extent that it is possible before the battle is joined in the operating room is clearly the safest and most valuable way to approach new surgical problems. (4) Willingness to return to the laboratory as further problems arise should be part of the surgeon's approach. (5) The surgeon should work within the laws of biology in devising new procedures. He must know what he can expect from tissue responses. Unless these can be modified as demonstrated experimentally, he must avoid wasting time and must work within these limits. (6)

Sustained and persistent efforts are generally needed to make forward movement.

I must add a corollary to the last point, which I hope will not be misconstrued. In dealing with apparently simple, yet complex problems that are not frequently encountered, such as tracheal reconstruction, the best results for our patients will be obtained if the work is concentrated in special units where a continuing commitment has been made to this type of work. Bad results are part and parcel of difficult operations, but I continue to be appalled by disasters that I see occur in what should be a simple airway operation. These are often the results of procedures done without appropriate thought or preparation.

I believe that we can summarize the last 25 years of tracheal surgery much as one could summarize the first 25 years of pulmonary surgery, of esophageal surgery, and of cardiac surgery. In each case what appeared to be a difficult and relatively untried area of surgery was entered with considerable success. However, without in any sense derogating what has been done, we note that the strides made by the "buccaneer surgeons" in each case have been relatively easy conquests *in retrospect*. Further



Fig 25. Professor Mikhail Perelman, Head of the Department of Thoracic Surgery of the National Centre of Surgery, Moscow, one of the world's most experienced tracheal surgeons. He is a skilled and innovative surgeon who has published many papers and three monographs on tracheal, bronchial, and pulmonary surgery.



Fig 26. Professor Henri Eschaspasse of Toulouse (left) with Dr Pearson in 1981 before a meeting in Bordeaux. Professor Eschaspasse has been especially interested in the treatment of tracheal tumors.

advances will require more sophisticated effort because the problems are more complex and more refined. Real advances may therefore be more difficult.

One of the most satisfying aspects of this personal odyssey has been to work with a succession of talented young residents. It is gratifying to see how easily the techniques of tracheal surgery may be transferred to the apt and willing pupil. A measure of the validity of an operation is that it may be taught successfully. From working with these extremely able young thoracic surgeons, I have every confidence that they and their peers will continue to change and improve thoracic surgery, however difficult the next stages may be.

I shall close with a few words directed to young thoracic surgeons. When I expressed an interest as a young surgeon in working in general thoracic surgery, I was cautioned by a distinguished thoracic surgeon, "Hermes, everything has been done in thoracic surgery." A few years later a noted British thoracic surgeon was escorted through the laboratory where I was working on our early tracheal experiments. He listened, looked briefly, and said only three words: "It won't work." Then he turned on his heel and left. Do not let us—your seniors—discourage you with such words or by pronouncements of immutable rules. Remain skeptical, work carefully and reasonably, and you may rewrite the rules—at least for a time.

References

1. Ravitch MM. Progress in resection of the chest wall for tumor with reminiscences of Dr. Blalock. *J Hopkins Med J* 1982;151:43.
2. Scannell JG. Samuel Robinson, pioneer thoracic surgeon (1875-1947). *Ann Thorac Surg* 1986;41:692.
3. Paré A. The case reports and autopsy records of Ambroise Paré. Hamby WB, ed. Springfield, Ill: C.C. Thomas, 1960:47-9.
4. Grillo HC. Surgery of the trachea: current problems in surgery. Chicago: Year Book Publishers, 1970.
5. Belsey R. Resection and reconstruction of the intrathoracic trachea. *Br J Surg* 1950;38:200.
6. Grillo HC, Watts GT, Gross J. Studies in wound healing. I. Contraction and the wound contents. *Ann Surg* 1958;148:153.
7. Grillo HC, Gross J. Collagenolytic activity during mammalian wound repair. *Develop Biol* 1967;15:300.
8. Grillo HC, Gross J. Thermal reconstitution of collagen and the response to heterologous implantation. *J Surg Res* 1962;2:69.
9. Grillo HC, Dignan EF, Miura T. Experimental reconstruction of cervical trachea after circumferential excision. *Surg Gynecol Obstet* 1966;123:99.
10. Grillo HC, Dignan EF, Miura T. Extensive resection and reconstruction of mediastinal trachea without prosthesis or grafts: an anatomical study in man. *J Thorac Cardiovasc Surg* 1964;48:741.
11. Michelson E, Solomon R, Maun L, Ramirez J. Experiments in tracheal reconstruction. *J Thorac Cardiovasc Surg* 1961;41:748.
12. Grillo HC, Bendixen HH, Gephart T. Resection of the carina and lower trachea. *Ann Surg* 1963;158:889.
13. Grillo HC. Carinal reconstruction. *Ann Thorac Surg* 1982;34:356.
14. Grillo HC. Circumferential resection and reconstruction of mediastinal and cervical trachea. *Ann Surg* 1965;162:374.
15. Mulliken JB, Grillo HC. The limits of tracheal resection with primary anastomosis. *J Thorac Cardiovasc Surg* 1968;55:418.
16. Dedo HH, Fishman NH. Laryngeal release and sleeve resection for tracheal stenosis. *Ann Otol Rhinol Laryngol* 1969;78:285.
17. Montgomery WW. The surgical management of supraglottic and subglottic stenosis. *Ann Otol Rhinol Laryngol* 1968;77:534.
18. Cooper JD, Grillo HC. The evolution of tracheal injury due to ventilatory assistance through cuffed tubes: a pathologic study. *Ann Surg* 1969;169:334.
19. Florange W, Muller V, Forster E. Morphologie de la nécrose trachéale apres trachéotomie et utilisation d'une prothese respiratoire. *Anesth Analg* 1965;22:693.
20. Grillo HC. The management of tracheal stenosis following assisted respiration. *J Thorac Cardiovasc Surg* 1969;57:52.
21. Pearson FG, Goldberg M, deSilva AJ. Tracheal stenosis complicating tracheostomy with cuffed tubes: clinical experience and observations from a prospective study. *Arch Surg* 1968;97:380.
22. Miura T, Grillo HC. The contribution of the inferior thyroid artery to the blood supply of the human trachea. *Surg Gynecol Obstet* 1966;123:99.
23. Salassa JR, Pearson BW, Payne WS. Gross and microscopical blood supply of the trachea. *Ann Thorac Surg* 1977;24:100.
24. Cooper JD, Grillo HC. Experimental production and prevention of injury due to cuffed tracheal tubes. *Surg Gynecol Obstet* 1969;129:1235.
25. Grillo HC, Cooper JD, Geffin B, Pontoppidan H. A low-pressure cuff for tracheostomy tubes to minimize tracheal injury. *J Thorac Cardiovasc Surg* 1971;62:898.
26. Maeda M, Grillo HC. Tracheal growth following anastomosis in puppies. *J Thorac Cardiovasc Surg* 1972;64:304.
27. Maeda M, Grillo HC. Effect of tension on tracheal growth

- after resection and anastomosis in puppies. *J Thorac Cardiovasc Surg* 1973;65:658.
28. Kotake Y, Grillo HC. Reduction of tension at the anastomosis following tracheal resection in puppies. *J Thorac Cardiovasc Surg* 1976;71:600.
 29. Grillo HC, Zannini P. Management of obstructive tracheal disease in children. *J Pediatr Surg* 1984;19:414.
 30. Grillo HC. Tracheal tumors: surgical management. *Ann Thorac Surg* 1978;26:112.
 31. Grillo HC. Surgical treatment of post-intubation tracheal injuries. *J Thorac Cardiovasc Surg* 1979;78:860.
 32. Grillo HC, Moncure AC, McEnany MT. Repair of inflammatory tracheoesophageal fistula. *Ann Thorac Surg* 1976;22:112.
 33. Grillo HC. Congenital lesions, neoplasms, and injuries of the trachea. In: Sabiston D, Spencer F, eds. *Gibbon's surgery of the chest*, 4th Ed. Philadelphia: WB Saunders, 1983:274-6.
 34. Grillo HC. Primary reconstruction of airway after resection of subglottic laryngeal and upper tracheal stenosis. *Ann Thorac Surg* 1982;33:2.
 35. Couraud L, Martigue C, Houdelette P, et al. Intérêt de la résection cricoïdienne dans le traitement des sténoses crico-trachéales apres intubation. *Ann Chir Thorac Cardiovasc* 1979;33:242.
 36. Gerwat J, Bryce DP. The management of subglottic laryngeal stenosis by resection and direct anastomosis. *Laryngoscope* 1974;84:940.
 37. Pearson FG, Cooper JD, Nelems JM, VanNostrand AWP. Primary tracheal anastomosis after resection of cricoid cartilage with preservation of recurrent laryngeal nerves. *J Thorac Cardiovasc Surg* 1975;70:806.
 38. Grillo HC, Zannini P, Michelassi F. Complications of tracheal reconstruction: incidence, treatment and prevention. *J Thorac Cardiovasc Surg* 1986;91:322.
 39. Landa L. The tracheal T tube in tracheal surgery. In: Grillo HC, Eschapaspe H, eds. *International trends in general thoracic surgery*. Vol 2. Philadelphia: WB Saunders, 1987: 124-32.
 40. Waddell WR, Cannon B. Technic for surgical excision of the trachea and establishment of sternal tracheostomy. *Ann Surg* 1959;149:1.
 41. Grillo HC. Terminal or mural tracheostomy in the anterior mediastinum. *J Thorac Cardiovasc Surg* 1966;51:422.
 42. Mathisen DJ, Grillo HC, Vlahakes G, Daggett W. The omentum in the management of complicated cardiothoracic problems. *J Thorac Cardiovasc Surg* 1988;95:677.
 43. Jensik RJ, Faber LP, Kittle CF, Miley RW, Tratcher WC, El-Baz N. Survival in patients undergoing tracheal sleeve pneumonectomy for bronchogenic carcinoma. *J Thorac Cardiovasc Surg* 1982;84:489.
 44. Grillo HC, Zannini P. Resectional management of airway invasion by thyroid carcinoma. *Ann Thorac Surg* 1986;42:287.
 45. Churchill ED. General education in surgery [Editorial]. *Ann Surg* 1956;144:506.
 46. Cope O. Foreword. *Ann Surg* 1963;158:731.
 47. Scannell JG. As I remember them. *J Thorac Cardiovasc Surg* 1978;76:145.
 48. Warren R. Edward Delos Churchill 1895-1972. *Trans Am Surg Assoc* 1973;91:38.
 49. Snyder HE. Edward Delos Churchill (1895-1972). *J Thorac Cardiovasc Surg* 1973;66:153.
 50. Wilkins EW Jr. Richard H. Sweet. In: Castleman B, Crockett DC, Sutton SB, eds. *The Massachusetts General Hospital 1955-1980*. Boston: Little, Brown, 1983.
 51. Geffin B, Bland J, Grillo HC. Anesthetic management of tracheal resection and reconstruction. *Anesth Analg* 1969;48: 884.
 52. Wilson RS. Anesthetic management for tracheal reconstruction. In: Grillo HC, Eschapaspe H, eds. *International trends in general thoracic surgery*. Vol 2. Philadelphia: WB Saunders, 1987:3-12.
 53. Momose KJ, MacMillan AS Jr. Roentgenologic investigations of the larynx and trachea. *Radiol Clin North Am* 1978;16:321.
 54. Weber LA, Grillo HC. Tracheal tumors: a radiological, clinical and pathological evaluation of 84 cases. *Radiol Clin North Am* 1978;16:227.
 55. Spizarny DL, Shepard JO, McLoud TC, Grillo HC, Dedrick CG. CT of adenoid cystic carcinoma of the trachea. *Am J Radiol* 1986;146:1129.
 56. Mark EJ. Pathology of tracheal neoplasms. In: Choi NC, Grillo HC, eds. *Thoracic oncology*. New York: Raven Press, 1983:257-69.
 57. Al-Bazzaz F, Grillo HC, Kazemi H. Response to exercise in upper airway obstruction. *Am Rev Respir Dis* 1975;111:631.
 58. Nissen R. Tracheoplastik zur Beseitigung der Erschaffung des membranosen Teils der Intrathorakalen. *Luftrohre Schweiz Med Wochenschr* 1954;84:219.
 59. Herzog H, Heitz M, Keller R, Graedel E. Surgical therapy for expiratory collapse of the trachea and large bronchi. In: Grillo HC, Eschapaspe H, eds. *International trends in general thoracic surgery*. Vol 2. Philadelphia: WB Saunders, 1987:74-90.
 60. Shepard JO, Grillo HC, McLoud TC, Dedrick CG, Spizarny DL. Right pneumonectomy syndrome: radiologic findings and CT correlation. *Radiology* 1986;161:661.